

# Peripheral Nerve Imaging using 2-point Dixon 3D Fast Spin Echo (CUBE-FLEX) with Flow-Saturation Preparation (FSP): Initial Feasibility Study



Darryl B. Sneag<sup>1</sup>, Mitsuharu Miyoshi<sup>2</sup>, Maggie Fung<sup>3</sup>, Tina Jeon<sup>1</sup>, Hollis G. Potter<sup>1</sup>

<sup>1</sup>Hospital for Special Surgery, New York, NY; <sup>2</sup>GE Healthcare, Hino, Japan; <sup>3</sup>GE Healthcare, New York, NY

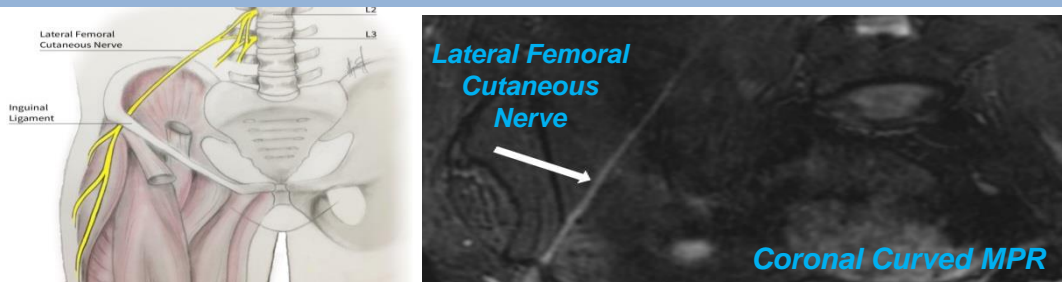
## Purpose

Peripheral nerves pose particular imaging challenges due to their small size and oblique course between muscles and alongside vessels, sometimes inhibiting reliable identification. We propose a 2-point Dixon fat/water separation 3D fast spin echo (CUBE-FLEX) pulse sequence to achieve uniform fat suppression, combined with a flow-saturation preparation pulse (FSP) to suppress moving vascular spins, thereby improving nerve visualization.

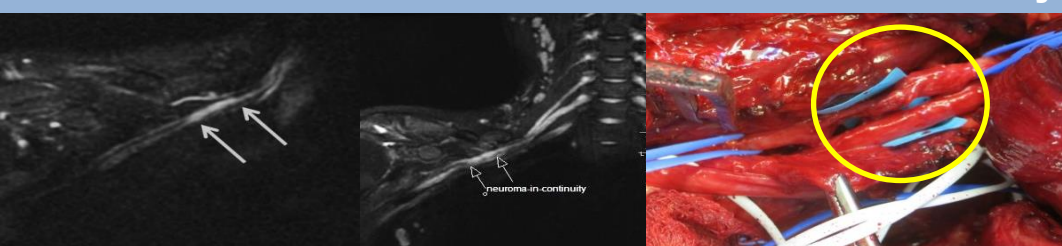
## Methods

98 consented patients scanned on a GE 3T 60cm bore scanner (MR750, GE Healthcare, Waukesha, WI) using 16ch flexible extremity or 32ch body arrays. A 3D FSE technique with modulated flip angle (CUBE) was used and applied to peripheral nerve imaging at various anatomical locations including: brachial/lumbosacral plexi, deep pelvis, and upper extremities. Representative imaging parameters: FOV:36x36cm, Matrix:256x256, TR/TE:2000ms/75ms, ETL: 120, BW:±125kHz, Slice thickness:1.6mm, avgs:1, Acceleration: 1.5, # slices: 232, time: 4-6min.

## 73 yo woman with Meralgia Paresthetica

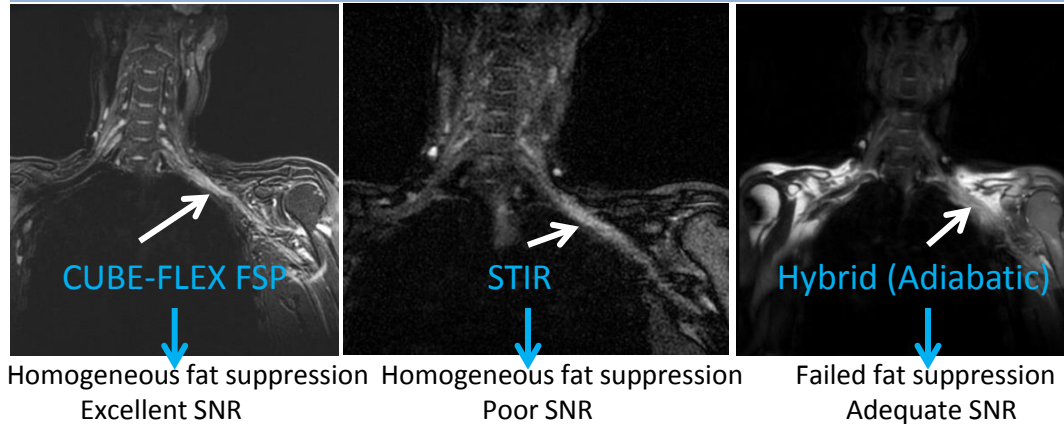


## Snowmobile accident: Posterior Cord Neuroma-in-Continuity



37 yo man 4 months status post snowmobile accident. Coronal CUBE-FLEX FSP images of the right brachial plexus demonstrate neuroma-in-continuity of the posterior cord (arrows). The corresponding intra-operative photograph demonstrates the damaged nerves (axillary and radial nerve bundles of the posterior cord) following removal of dense perineural scar tissue.

## Comparison between Different Fat Suppression Techniques for the Brachial Plexus In a Volunteer



CUBE-FLEX FSP

STIR

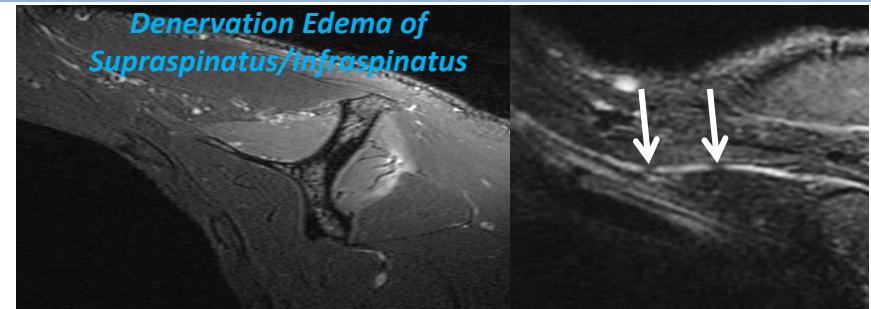
Hybrid (Adiabatic)

Homogeneous fat suppression  
Excellent SNR

Homogeneous fat suppression  
Poor SNR

Failed fat suppression  
Adequate SNR

## 23 yo man with Parsonage-Turner Syndrome: Focal Intrinsic Constrictions of Suprascapular Nerve



## Conclusion

Using the CUBE-FLEX FSP technique, we observed homogeneous fat suppression, excellent contrast between nerves and surrounding tissues, and the added advantage of venous suppression in the plexi. Remaining challenges include B1 inhomogeneity creating a shading effect and incomplete signal suppression of slow flow veins in the deep pelvis and extremities.

## References/Acknowledgments

[1] Ma J Magn Reson Med, 2004 [2] Miyoshi M, ISMRM 2007 Proceeding P.180.

\*\*The authors would like to Jung Joo RT-(R)(MR) for his assistance with this project.